

Obstructive sleep apnea treatment with a twopiece mandibular advancement device with an elastic retention band in combination with orofacial myofunctional therapy: a case report

Arisa Ebato¹
Hiroshi Suzuki¹
Tatsuo Sakamaki²
Sumito Ooguchi²
Chin Moi Chow³
Osamu komiyama¹

¹ Nihon University School of Dentistry at Matsudo, Division of oral function and Rehabilitation, Department of Oral health science - Matsudo - Chiba - Japan.

² Nihon University School of Dentistry at Matsudo, Department of Internal Medicine - Matsudo - Chiba - Japan.

³ University of Sydney, Charles Perkins Centre, University of Sydney and Exercise, Health & Performance Research Group, Faculty of Health Sciences - Sydney - NSW - Australia.

ABSTRACT

Two-piece mandibular advancement devices (MAD) are considered more comfortable than monoblock devices, and they are commonly used for the treatment of obstructive sleep apnea (OSA). However, they are not without limitations, especially in patients with nasal obstruction/malocclusion. Here, we discuss the case of a 37-year-old woman with mandibular regression and severe OSA, for whom a standard twopiece MAD was not adequately effective. However, her sleep apnea improved with concurrent treatment with lip-muscle training (orofacial myofunctional therapy, OMFT) and a two-piece oral appliance (OA) supplemented with an elastic retention band (ERB). The OMFT improved lip muscle strength. In particular, the ERB restricted mouth opening. The application of OMFT together with an OA and ERB was a good option for this patient. Future clinical trials should include a three-arm study involving the OMFT (with measurement of lip-closure force, reflecting the degree of mouth opening), the two-piece OA with an ERB, and combined treatment.

Keywords: Two-piece oral appliances; Lip muscle training; Lip closure force.

Corresponding author: Hiroshi Suzuki.
E-mail: maar17004@gnihon-u.ac.jp
Received: May 16, 2018; Accepted:
December 16, 2018.

DOI: 10.5935/1984-0063.20190050

INTRODUCTION

Obstructive sleep apnea (OSA) is considered severe with a respiratory disturbance index (RDI) of ≥ 30 . However, in Japan, continuous positive airway-pressure treatment using national insurance is accessible only when the RDI is ≥ 40 . Thus, oral appliances (OAs) constitute the primary form of treatment for Japanese patients with OSA.

OAs reposition the lower jaw forward to increase upper airway opening, reducing its collapsibility¹. These appliances are generally divided into two categories. Devices that apply traction force to maintain the mandible in a forward position are known as mandibular advancement devices (MADs)², while those that maintain the tongue in a forward-projected position are known as tongue-retaining devices³. Among MADs, two-piece devices are advantageous over monoblock ones. They are more comfortable, allow jaw movement while worn, and place less stress on the temporomandibular joint, muscle tissues, and other structures⁴. However, two-piece MADs are not without disadvantages, since the ease of jaw movement may cause mouth opening, which in turn modifies the forward positioning of the lower jaw and reducing device efficacy. Applying an elastic retention band (ERB) has the advantage of resisting mouth opening⁵. Here, we discuss the case of a patient with severe OSA, for whom a standard two-piece MAD was not adequately effective, but supplementing the treatment with an ERB and orofacial myofunctional therapy (OMFT, a program of exercises that improves lip muscle strength and co-ordination of the muscles of the face and tongue), leading to improvement in sleep apnea symptoms.

CASE REPORT

A 37-year-old woman (body mass index: 15.1 kg.m⁻²; facial profile: convex type with a regressed mandible) visited our hospital for treatment for snoring and excessive daytime drowsiness. She slept for an average of approximately 6 h per night on weekdays and scored 15 on the Epworth Sleepiness Scale⁶. On the basis of the results of a Level III sleep test (a portable home sleep study), she was diagnosed with severe OSA (RDI = 33.5 per hour; lowest oxygen saturation level, 84.0%; Table 1). Sleep data were scored according to AASM guidelines⁷. The diagnosis was made only by a simple sleep test because the patient (against the advice of clinicians) did not wish to undergo a full polysomnography test requiring a hospital stay due to her family situation.

Table 1. Course of treatment and results of the sleep test.

	First test	Second test	Third test	Fourth test	
Day	Day 0	Day 10	Day 20	Day 74 (two months later from second test)	
RDI (times/h)	33.5	31.9	8.1	6.4	7.6
SpO ₂ ave (%)	97.0	96.0	97.0	97.0	97.0
SpO ₂ min (%)	84.0	84.0	90.00	92.0	91.0
ESS	15	-	8	8	
LCF max (N)	-	4.8	-	7.2	
LCF min (N)	-	1.2	-	5.1	
ERB	-	-	+	+	-

The results of a detailed orthodontic test revealed an overjet of 6.9 mm, overbite of 3.0 mm, and Angle Class-II malocclusion. Lateral X-ray findings revealed skeletal Class-II malocclusion and a severe dolichofacial type, at which point corrective surgery was recommended (Figure 1). Since her family situation made hospitalization impossible, the patient was treated using a two-piece OA (mandibular advancement splint, SomnoMed®, Sydney, Australia). Because of her severe dolichofacial type, the titration of the mandible was set at about 80% of the maximum forward movement distance (Figure 1).

After ten nights of sleeping with the OA in place, the patient felt that she had slept well, although her snoring had not resolved and she continued to experience dry mouth. Her husband reported that her snoring had decreased but had not disappeared and that she slept with her mouth open. Because the patient felt no discomfort in the temporomandibular joint or other structures, the mandible was moved forward by 1 mm. The results of a further sleep test revealed an RDI of 31.9 per hour and a lowest oxygen saturation level of 84.0%, indicating no improvement (Table 1). At this point, we suspected that her lip-closure force (LCF) might be weak. Inadequate LCF was associated with mouth opening during sleep⁸. Additionally, we had previously reported that lip-muscle training (orofacial myofunctional therapy: OMFT) significantly reduced the Apnea-Hypopnea Index resulting from the increased LCF⁹. In this patient, OMFT was implemented using the M-Patakara® lip trainer (Patakara, Tokyo, Japan) made from flexible, resilient plastic and rubber. LCF, LCFmax (maximum) and LCFmin (minimum), each obtained in a 10-s period, were reported as the mean of 3 measurements with a

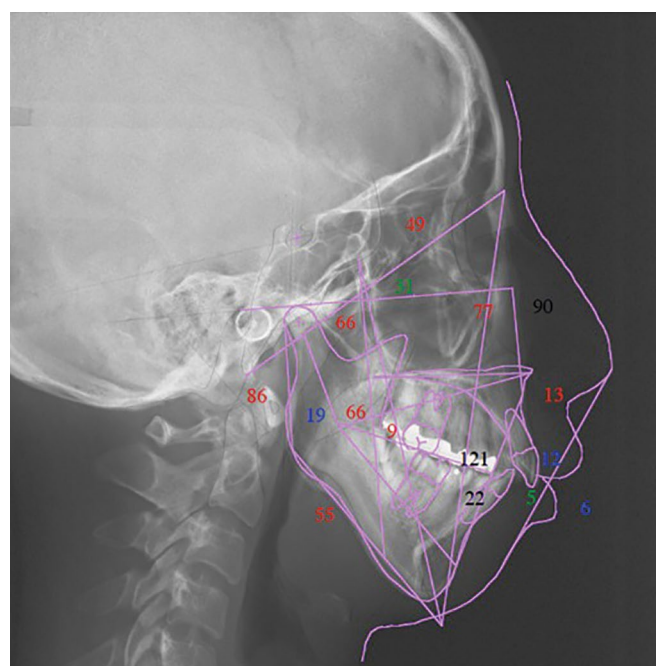


Figure 1. The findings of lateral cephalometric analysis revealed skeletal Class-II malocclusion (A point, nasion, B point angle: 12.0°) and a severe dolichofacial type (Frankfurt mandibular plane angle: 55.0°).

lip device (BHC-V01; Patakara Tokyo). In accordance with the supplied instructions for use of the Patakara[®], training involved 4 sessions/day, 5 min/session for 2 months. LCF data showed large improvements following training. Thus, we decided to conduct baseline measurements for LCF of the patient and obtained LCFmax and LCFmin values of 4.8 and 1.2 N, respectively (Table 1). Following this, the patient agreed to receive OMFT. Considering that her LCF values were low and that she continued to experience snoring and dry mouth with the two-piece OA, a consensus was reached that the patient should commence OMFT with the OA, and an ERB should be added to prevent her from sleeping with her mouth open (Figure 2).

Within a week, the snoring and dry mouth had completely resolved, and the patient felt that she was sleeping soundly. The results of an outpatient sleep test (third sleep test) revealed dramatic improvement when using the OA with an ERB, with an RDI of 8.1 per hour and a lowest oxygen saturation level of 90.0% (Table 1). The patient reported that she no longer experienced daytime drowsiness, and her Epworth Sleepiness Score decreased from 14 to 8 (Table 1).

Two months after OMFT with OA treatment, a fourth sleep test was conducted with and without the ERB (Table 1). The maximum and minimum LCF values of the patient had increased to 7.2 and 5.1 N, respectively, and her sleep data showed improvement, with an RDI of 6.4 per hour and a lowest oxygen saturation level of 92.0% when using the OA with an ERB. However, when using the OA without the ERB, the patient exhibited an RDI of 7.6 per hour and a lowest oxygen saturation level of 91.0% (Table 1). She is currently continuing to use the two-piece MAD with an ERB and is being monitored to determine when it can be discontinued.

DISCUSSION

Two-piece OAs are often recommended because they are considered more comfortable for patients than

monoblock devices. However, patients using two-piece OAs often sleep with their mouth open, especially when they have inadequate LCF or difficulty breathing through the nose because of nasal obstruction. In many cases in our clinic, two-piece OAs are not adequately effective for such patients.

In the present case, the patient did not have any nasal obstruction, although she had low maximum and minimum LCF values (4.8 and 1.2 N, respectively). Previous studies involving Japanese patients with OSA and low LCF have reported that OMFT improves the AHI and oxygen saturation levels during sleep, increases LCF, improves sleep quality¹⁰, and eliminates dry mouth/halitosis upon awakening¹¹. In the present case, by implementing a concurrent treatment protocol involving OMFT and an OA with an ERB to restrict mouth opening and compensate for the limitations of the two-piece OA, we observed an improvement in LCF levels, RDI, and lowest oxygen saturation. From these results, we judge that it may be feasible to remove the ERB from the OA providing that the LCF is maintained. However, because of her reluctance towards receiving the OMFT therapy, it may be difficult for the patient to continue lip muscle training to maintain the improved LCF. Nevertheless, she is content to use the OA with an ERB.

It is clear that keeping the mouth closed through the use of an OA with an ERB during sleep, and increasing lip-muscle strength through OMFT have beneficial effects for this patient with sleep apnea and low LCF. However, we are unable to tease out the beneficial effects attributable to OMFT, mandibular advancement, or a combined effect. Future randomized controlled trials should examine the efficacy of each treatment arm, including the combined-treatment arm. We believe that adequate assessment of the degree of mouth opening with pretreatment LCF measurement, followed by treatment with an ERB as necessary, will ultimately improve the efficacy and reliability of treatment with two-piece OAs.

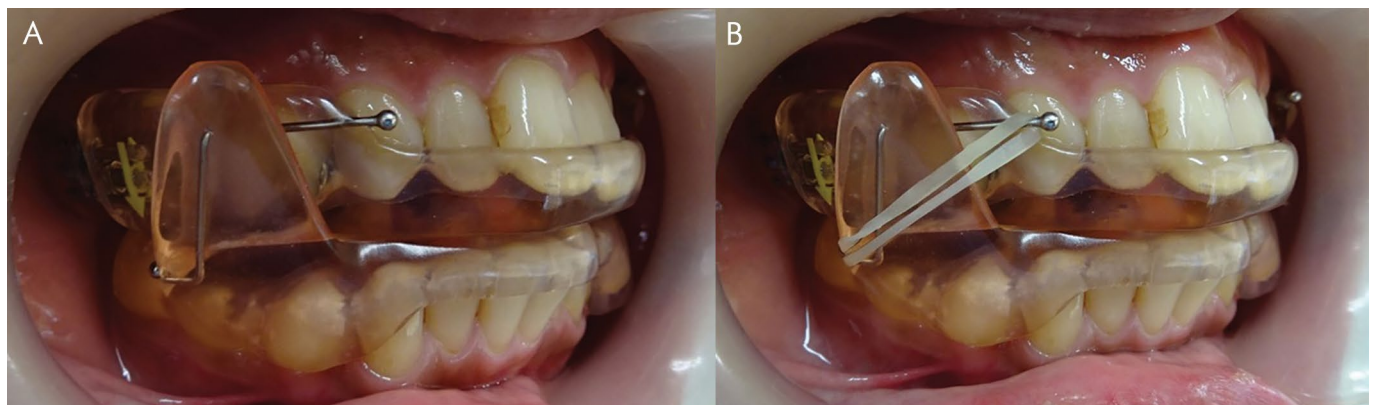


Figure 2. Two-piece mandibular advancement device without elastic retention band (2a) and with elastic retention band (2b).

REFERENCES

1. Sutherland K, Chan AS, Cistulli PA. Three-dimensional assessment of anatomical balance and oral appliance treatment outcome in obstructive sleep apnoea. *Sleep Breath*. 2016;20(3):903-10.
2. Lee WH, Wee JH, Lee CH, Kim MS, Rhee CS, Yun PY, et al. Comparison between mono-bloc and bi-bloc mandibular advancement devices for obstructive sleep apnea. *Eur Arch Otorhinolaryngol*. 2013;270(11):2909-13.
3. Deane SA, Cistulli PA, Ng AT, Zeng B, Petocz P, Darendeliler MA. Comparison of mandibular advancement splint and tongue stabilizing device in obstructive sleep apnea: a randomized controlled trial. *Sleep*. 2009;32(5):648-53.
4. de Almeida FR, Lowe AA, Tsuiki S, Otsuka R, Wong M, Fastlicht S, et al. Long-term compliance and side effects of oral appliances used for the treatment of snoring and obstructive sleep apnea syndrome. *J Clin Sleep Med*. 2005;1(2):143-52.
5. Chung JW, Enciso R, Levendowski DJ, Morgan TD, Westbrook PR, Clark GT. Treatment outcomes of mandibular advancement devices in positional and nonpositional OSA patients *Oral Surg Oral Med Oral Pathol Oral Radiol Endod*. 2010;109(5):724-31.
6. Osman EZ, Osborne J, Hill PD, Lee BW. The Epworth Sleepiness Scale: can it be used for sleep apnoea screening among snorers? *Clin Otolaryngol Allied Sci*. 1999;24(3):239-41.
7. Iber C, Ancoli-Israel S, Chesson A, Quan S. The AASM manual for the scoring of sleep and associated events: rules, terminology and technical specifications. Westchester: American Academy of Sleep Medicine; 2007. p. 45-7.
8. Suzuki H, Watanabe A, Akihiro Y, Takao M, Ikematsu T, Kimoto S, et al. Pilot study to assess the potential of oral myofunctional therapy for improving respiration during sleep. *J Prosthodont Res*. 2013;57(3):195-9.
9. Suzuki H, Yoshimura M, Iwata Y, Oguchi S, Kawara M, Chow CM. Lip muscle training improves obstructive sleep apnea and objective sleep: a case report. *Sleep Sci*. 2017;10(3):128-31.
10. Yoshimiura M, Suzuki H, Tanaka H, Asakawa R, Chow CM, Kawara M. Lip muscle training improves halitosis and obstructive sleep apnea syndrome: a case report. *J Dent Sleep Med*. 2016;3(1):31-2.
11. Oksenberg A, Froom P, Melamed S. Dry mouth upon awakening in obstructive sleep apnea. *J Sleep Res*. 2006;15(3):317-20.